


Difficult Vascular Access More Options



Don't worry, I'll find a good site soon!

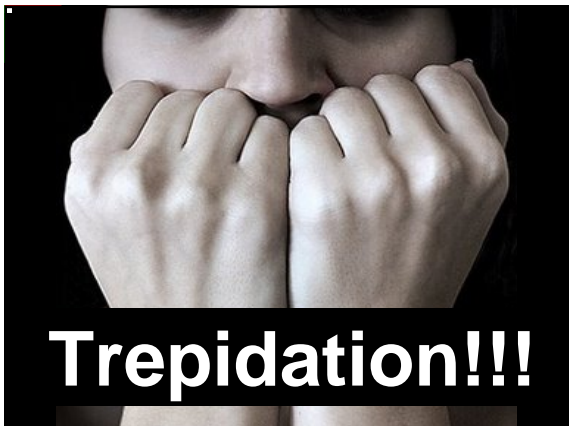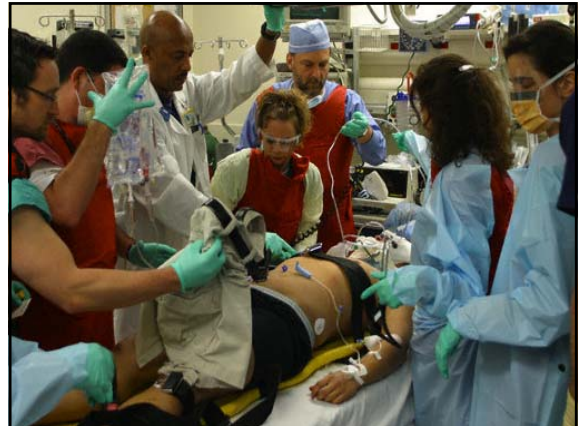Greg Schears, MD
Mayo Clinic, Rochester, MN

Learning Objectives

- Demonstrate and practice use of ultrasound to obtain peripheral venous access
- Demonstrate and practice use of two methods of intraosseous catheters to obtain emergent vascular access
- Identify the potential advantages of near infra-red technology to highlight / augment visualization of veins

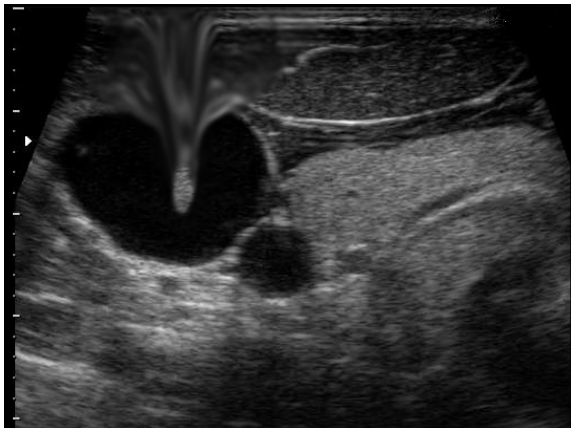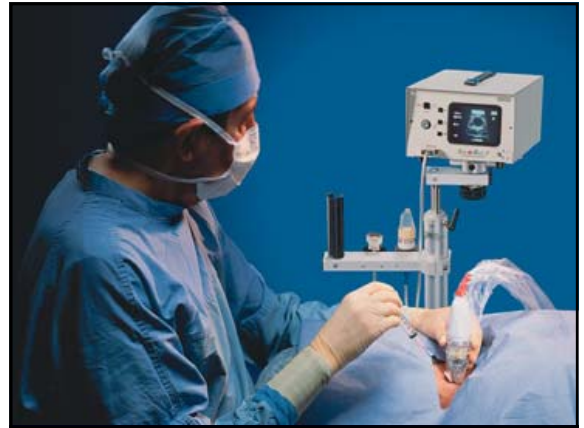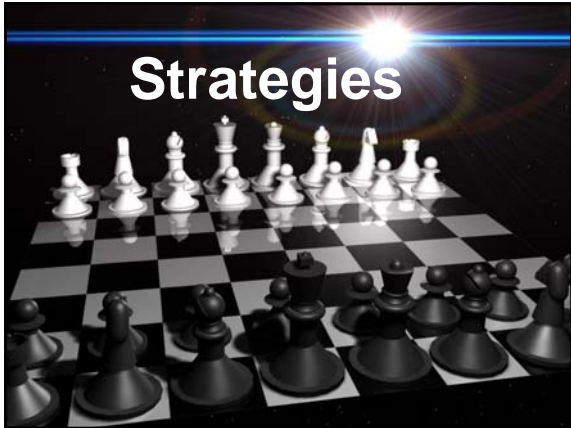DVA

- Could be Peripheral, Central, Arterial
- Dependent on factors and dynamic
 - Patient Condition
 - Clinician's Skill & Luck
 - Equipment Availability
- Easier to describe than define



Trepidation!!!

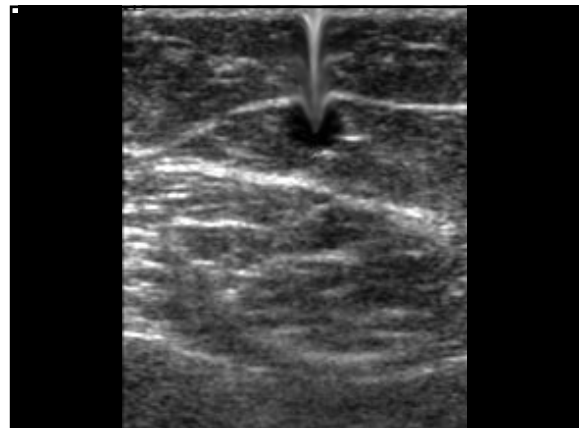
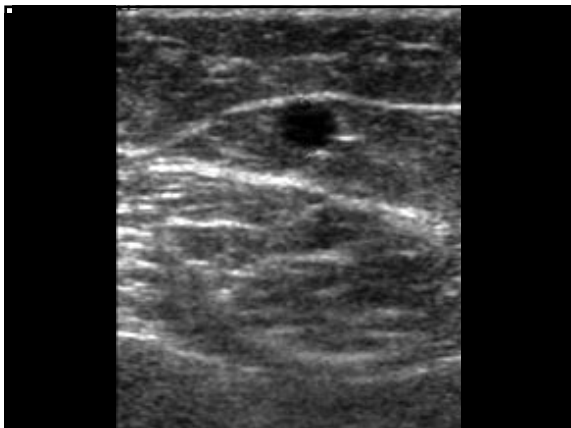


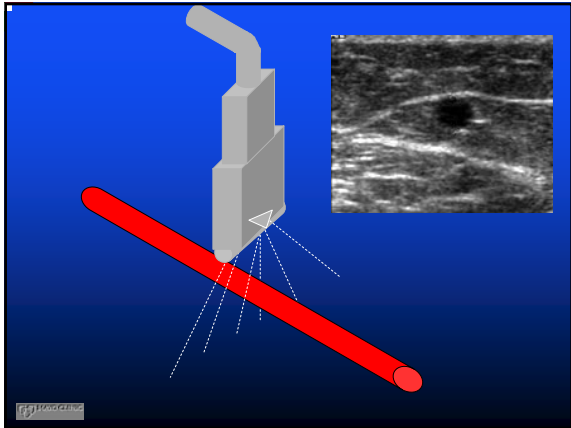


Case

- 11month old with multiple medical problems. Bronchoscopy to assess pulmon. process Known difficult access with thrombosed IJs and severe groin rash presumed fungal. Loses IV access during procedure.

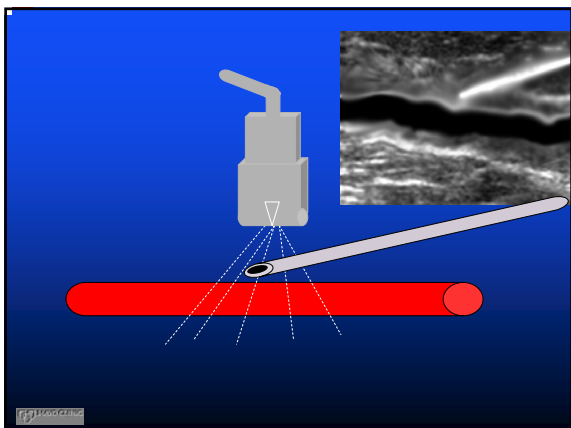
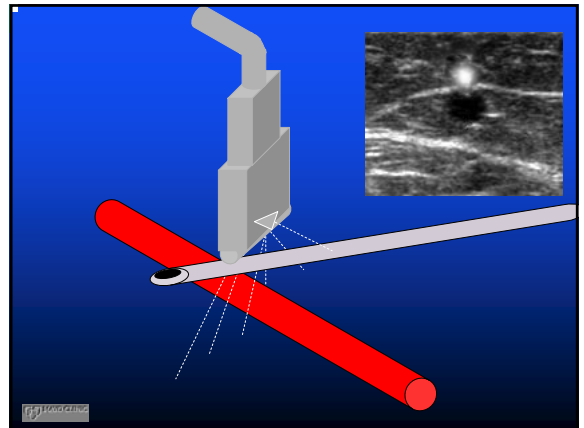
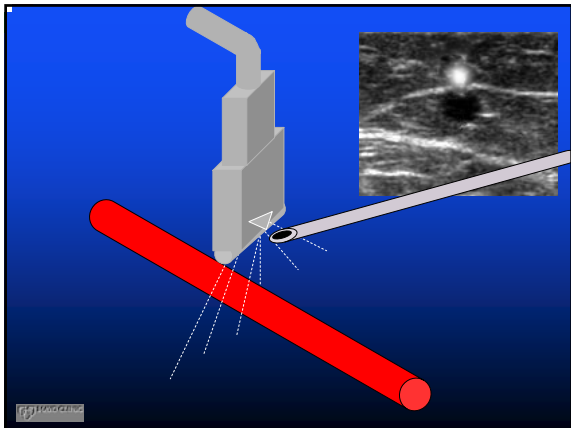
© 2011 Medtronic





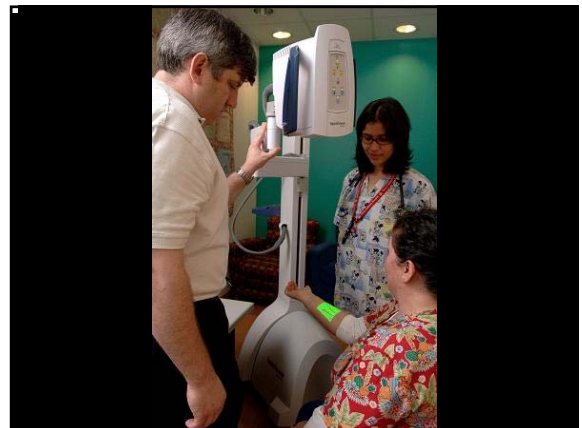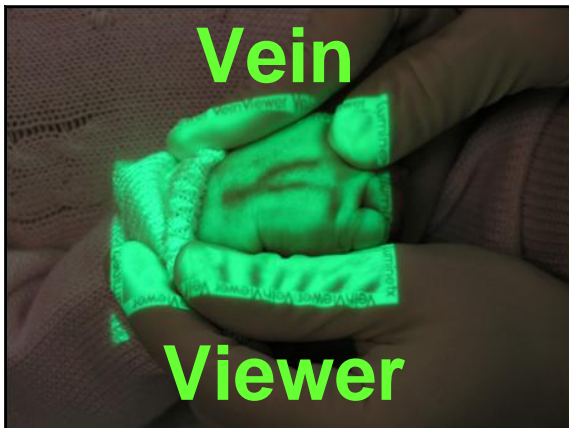
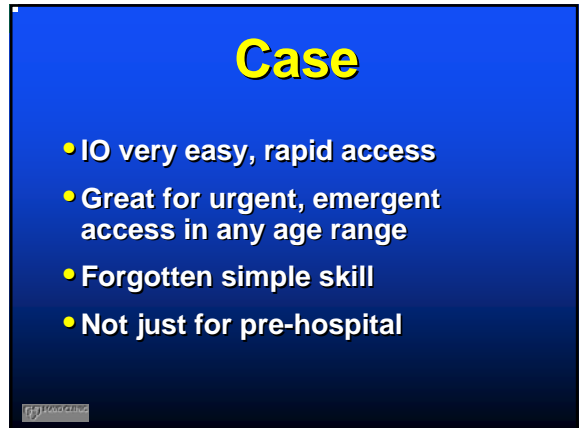
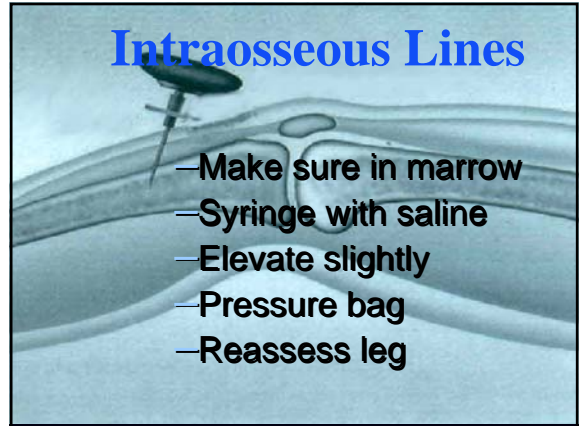
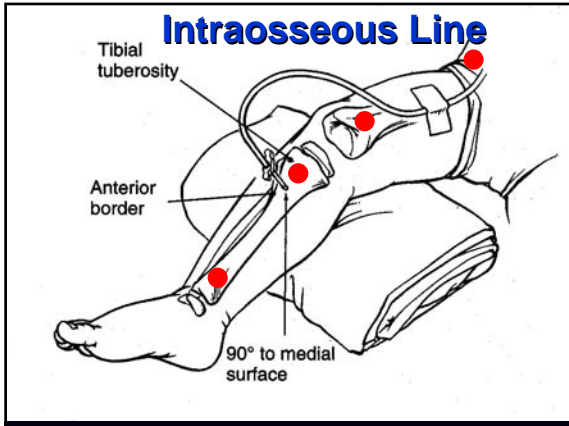
U / S Pearls

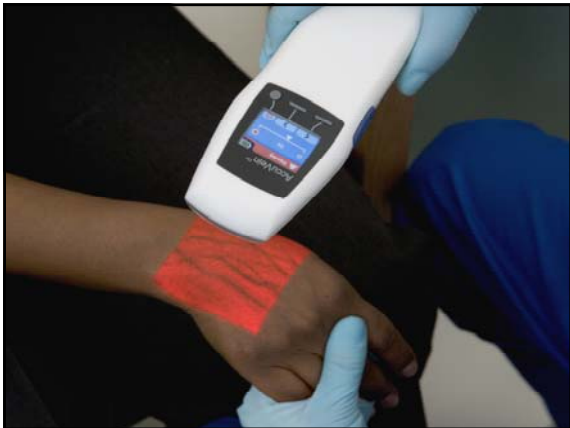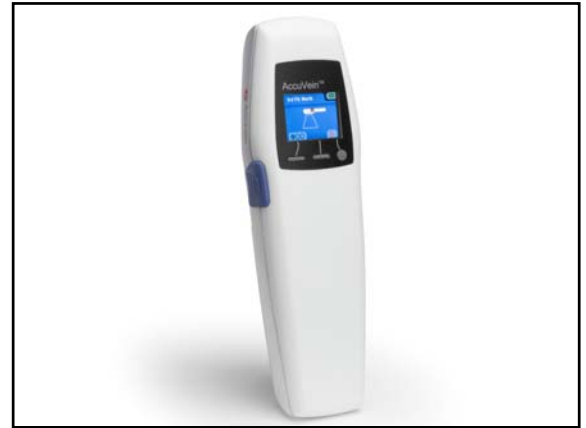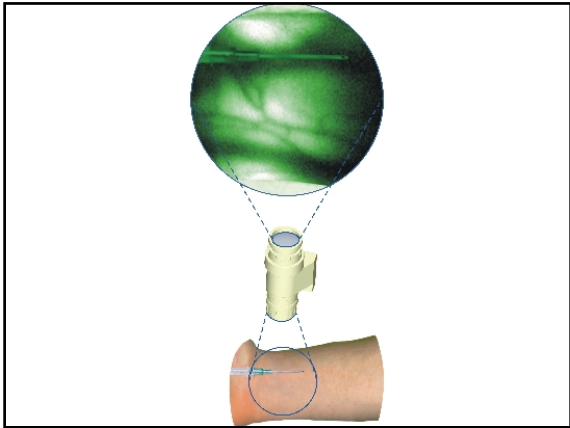
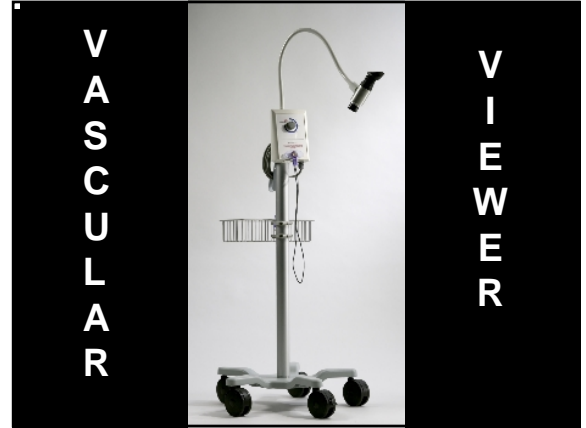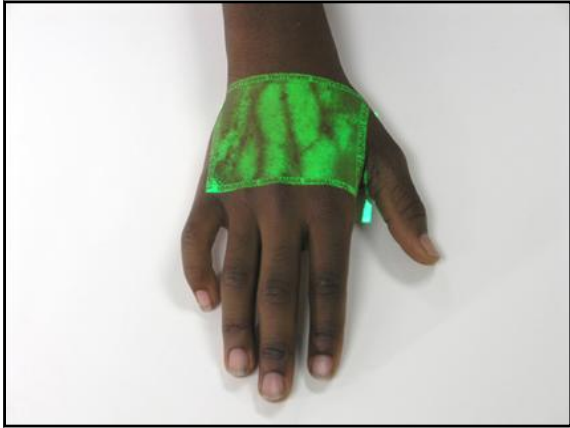- Proper transducer for depth / resolution
- Minimize depth setting
- Optimize the gain
- Use the centering guide line
- Bouncing on the vessel / color
- Relate images in 3-D
- Use longitudinal image if possible



Case

3 month old with complex congenital heart disease on dig., spironolactone, lasix and K⁺ supplements now 10 days post op preparing for discharge. No IV access, no labs monitored in two days because of difficult access. Develops peaked T waves, bradycardia, CA





Summary

- Anesthesiologist – Last Resource
- Technology – More Options
- U/S already available, learning curve
- I / O not just for pre-hospital
- NIR - Promising

© 2011 Masimo Corp.