NEONATE FOR REPAIR OF DIAPHRAGMATIC HERNIA ON ECMO

James Lynch, MD
Gregory Schears, MD
Mayo Clinic College of Medicine
Rochester, MN

OBJECTIVES

1. Review common treatment strategies in patients with diaphragmatic hernia
2. Discuss indications and contraindications for initiation of ECMO support
3. Review issues related to timing and location of surgical repair of diaphragmatic hernia in patients requiring support with extracorporeal membrane oxygenation (ECMO)
4. Review anesthetic options for patients on veno-arterial and veno-venous ECMO
5. Discuss management of anticoagulation for patients requiring surgical repair while on ECMO
6. Review risks and benefits of antifibrinolytic therapy for patients requiring surgical repair while on ECMO

STEM CASE – KEY QUESTIONS

A 3.5-kg, 51-cm girl with a prenatally diagnosed diaphragmatic hernia was born at 39-2/7 weeks via induced vaginal delivery to a healthy 25-year-old G1P0 mother. The neonate had strong spontaneous crying immediately after birth, with APGAR scores of 9 at both 1 and 5 minutes. Because of the known diaphragmatic hernia, she was intubated in the delivery room and remained adequately oxygenated on modest mechanical ventilation settings. However, on the second day-of-life her oxygen requirements increased requiring initiation of high-frequency oscillation ventilation (HFOV) and inhaled nitric oxide. Chest radiograph is shown in Figure 1. Severe pulmonary hypertension and right ventricular dysfunction were seen with transthoracic echocardiography. With increasing doses of inotrope (dopamine 15 mcg/kg/min) needed to support her hemodynamics, the decision was made to place the neonate on veno-arterial ECMO.

Cannulation of the right carotid artery (8-Fr) and right internal jugular vein (14-Fr) via cut-down was performed in the intensive care unit. ECMO flow was maintained between 1.5 and 2.0 liters/min/m^2. A vasopressin infusion was used initially to maintain a mean blood pressure >40 mmHg while the dopamine was weaned off. On ECMO-day 2 she underwent patent ductus arteriosus ligation via left thoracotomy to correct the persistent large left-to-right shunt.

On ECMO she was anticoagulated with heparin (4-16 units/kg/hour) to maintain an activated clotting time (ACT) (I-stat® with kaolin cartridge) of >160 seconds. On ECMO-days 3-4 she exhibited a mild coagulopathy requiring transfusion of fresh frozen

plasma, cryoprecipitate and platelets to maintain adequate coagulation parameters. Sedation was achieved with infusions of midazolam and morphine, and low concentrations (0.2-0.4% inspired) isoflurane. With little improvement of aeration due to persistent bilateral lung consolidation seen on multiple chest radiographs, she remained on HFOV (mean 14 cmH_2O, amplitude 36 cmH_2O, 8 hZ, FiO_2 21%).

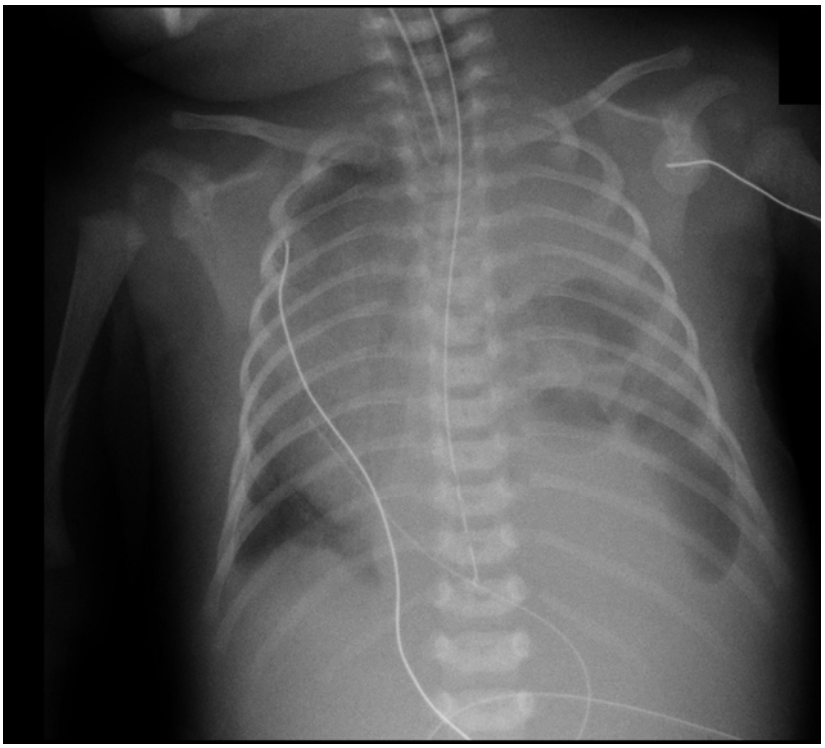

Figure 1. Chest radiograph from day-of-life 2 prior to initiation of ECMO

On ECMO-day 5 she was hemodynamically stable, and did not require any inotrope or vasopressor infusions. Her hemoglobin was 10.7 g/dL. Coagulation tests showed a prothrombin time (PT) of 11.6 sec, partial thromboplastin time (PTT) between 52-63 sec, fibrinogen of 147 mg/dL and a platelet count of 86,000/mm^3. Heparinase thromboelastogram (kaolin) showed R=16.7 mm, angle (α)= 28.7°, mean amplitude (MA)=50.1 mm and no fibrinolysis. On her morning chest radiograph, a large pneumothorax with pneumoperitoneum was visualized, presumably the result of barotrauma. Because of the pneumothorax, the HFOV mean pressure was reduced to 10 cmH_2O and amplitude reduced to 28 cmH_2O. Rather than simply placing a chest tube, the pediatric surgical team requested to repair the diaphragmatic hernia that day.

Figure 2. Chest radiograph from ECMO-day 5 with large pneumothorax and pneumoperitoneum

DISCUSSION

Treatment of CDH and Indications for ECMO Therapy

What are the different ventilation strategies/modes used in these patients? What is the role of nitric oxide, and surfactant? What cardiovascular and/or respiratory parameters determine the need for ECMO support? What measures of oxygenation are used as indications/contraindications for ECMO?

Once ECMO support has been initiated, there are several issues that need to be addressed prior to proceeding with diaphragmatic hernia repair.

Timing

We must ask if this is the optimal time for surgical repair. As some centers suggest, should repair be delayed until the patient can be weaned from ECMO, or until they are off ECMO completely? Will the repair at this time help lung aeration or hemodynamics improve? If proceeding with repair, is the patient in optimal condition for the procedure? Is repair in the intensive care unit appropriate, or would transporting the patient to the operating room provide better operating conditions?

Anesthetic Delivery

Does the fact that the patient is currently on ECMO affect your anesthetic technique? Does the ECMO cannulation (veno-arterial vs. veno-venous) affect your technique? Should the patient be maintained on HFOV, or converted to traditional mechanical ventilation for the procedure?

Anticoagulation

The anticoagulation required for ECMO remains a challenge, potentially leading to increased bleeding and transfusion requirement related to the surgical repair. Prior to proceeding with repair, what values for the various coagulation parameters will you consider adequate? How will you achieve these values in this patient? Will you adjust the rate of heparin infusion for the procedure and/or the postoperative period? What are your target ACT and PTT values for this time period? Will these be different if the entire circuit, including cannulas, are heparin-coated?

Antifibrinolyitc Therapy

Numerous studies suggest there are less ECMO-related bleeding and hemorrhagic complications with administration of the lysine analogues aminocaproic acid or tranexamic acid. However there are also reports of thrombotic events occurring when these agents are used. Will you administer aminocaproic acid or tranexamic acid during or after the procedure? What are potential circuit-related consequences of using these agents?

SELECT REFERENCES

1. Adolph V, Flageole H, Perreault T, Johnston A, Nguyen L, Youssef S, Guttman F, Laberge JM. Repair of congenital diaphragmatic hernia after weaning from extracorporeal membrane oxygenation. J Pediatr Surg 1995;30:349-52.

2. Austin MT, Lovvorn HN, 3rd, Feurer ID, Pietsch J, Earl TM, Bartilson R, Neblett WW, 3rd, Pietsch JB. Congenital diaphragmatic hernia repair on extracorporeal life support: a decade of lessons learned. Am Surg 2004;70:389-95; discussion 95.

3. Dimmitt RA, Moss RL, Rhine WD, Benitz WE, Henry MC, Vanmeurs KP. Venoarterial versus venovenous extracorporeal membrane oxygenation in congenital diaphragmatic hernia: the Extracorporeal Life Support Organization Registry, 1990-1999. J Pediatr Surg 2001;36:1199-204.

4. Downard CD, Betit P, Chang RW, Garza JJ, Arnold JH, Wilson JM. Impact of AMICAR on hemorrhagic complications of ECMO: a ten-year review. J Pediatr Surg 2003;38:1212-6.

5. Lally KP, Paranka MS, Roden J, Georgeson KE, Wilson JM, Lillehei CW, Breaux CW, Jr., Poon M, Clark RH, Atkinson JB. Congenital diaphragmatic hernia. Stabilization and repair on ECMO. Ann Surg 1992;216:569-73.

6. Rothenbach P, Lange P, Powell D. The use of extracorporeal membrane oxygenation in infants with congenital diaphragmatic hernia. Semin Perinatol 2005;29:40-4.

7. Rozmiarek AJ, Qureshi FG, Cassidy L, Ford HR, Hackam DJ. Factors influencing survival in newborns with congenital diaphragmatic hernia: the relative role of timing of surgery. J Pediatr Surg 2004;39:821-4; discussion -4.

8. van der Staak FH, de Haan AF, Geven WB, Festen C. Surgical repair of congenital diaphragmatic hernia during extracorporeal membrane oxygenation: hemorrhagic complications and the effect of tranexamic acid. J Pediatr Surg 1997;32:594-9.

9. Vazquez WD, Cheu HW. Hemorrhagic complications and repair of congenital diaphragmatic hernias: does timing of the repair make a difference? Data from the Extracorporeal Life Support Organization. J Pediatr Surg 1994;29:1002-5; discussion 5-6.

10. Wilson JM, Bower LK, Lund DP. Evolution of the technique of congenital diaphragmatic hernia repair on ECMO. J Pediatr Surg 1994;29:1109-12.