General Anesthesia without Endotracheal Intubation for Prone Craniospinal Radiation Therapy in Children

Author(s): P Ranganathan, Z Shiue, D Schwengel, S Kost-Byerly

Affiliation(s): The Johns Hopkins Medical Institutions, Baltimore, MD

Introduction: Children with posterior fossa tumors frequently require a course of daily craniospinal irradiation for several weeks. Radiation fields for the brain and spine cannot overlap because of the risk of toxic doses at the cervical cord level. Prone positioning of the patient facilitates exact location of the radiation fields but complicates airway management in patients requiring anesthesia. Airway manipulations on a daily basis may lead to airway trauma.

Methods: After obtaining Institutional Review Board and HIPAA approval we reviewed the medical records of children undergoing craniospinal irradiation in the prone position under general anesthesia between December of 1996 and May 2006. Data are presented as average ę SD.

Results: 10 children, averaging 40±20 (range 12-72) months of age, weighing 14.9 ± 4.5 (range 7.2-21) kg underwent radiation therapy in the prone position under general anesthesia. Patients had primary posterior fossa tumors (N=9) or ALL metastatic to the brain (N=1). Prior to radiation therapy patients had undergone craniotomies with tumor resections (N=7) or palliative VP shunt placements (N=2). Two patients had radiation limited to the brain whereas 8 received treatment of brain and spine. Patients had an average of 28 (range 7-34) treatments each. Total doses ranged between 1050-5940 Gy for the brain and 1050-4480 Gy for the spine. Complete anesthetic data sets were available for 7 patients (165 procedures) at the time of this writing. We plan to include the remaining patients at the time of presentation. During simulation each patient had an individually fitted polymer crate made with particular attention paid to the patency of the airway in the prone position. All patients had ECG, noninvasive BP, O2 Sat, and ETCO2 monitoring. Children had a simple facemask for oxygen delivery while in the prone position during all but 22 procedures (LMA 7, ETT 15). A single patient had 30% of the LMA/ETT placements. Anesthesia was induced and maintained with propofol. Induction doses averaged 4.8±1.1mg/kg and continuous infusion rates were 332±186 (range 120-950) mcg/kg/min. Excluding patient #8, propofol infusion rates were lower and more homogeneous (240±59 [range 120-350] mcg/kg/min). No apparent tolerance to propofol over time was noted. Midazolam was supplemented in 35 and fentanyl in 19 procedures. 25% of these doses were for child #8. One anesthesiologist administered 58% of fentanyl and 20% of midazolam doses although providing anesthesia for only 10% of the procedures (none for child #8). Procedures lasted 38±24 (range 7-150) minutes. Discharge from the PACU occurred after 40±17 (range 15-95) minutes. There were no serious complications; no patient required airway manipulations beyond the ones originally planed. Glycopyrolate was administered postoperative for a HR of 65 once. One child had emesis prior to induction on two occasions and coarse breath sounds postoperative after one of the events. These completely resolved before discharge from the PACU.

Conclusion: Taking the inherent limitations of a retrospective review into consideration it appears that general anesthesia without endotracheal intubation for prone craniospinal radiation therapy can be safely achieved in the hands of an experienced, vigilant pediatric anesthesiologist. Certain patients might have a need for higher doses of propofol or supplementation with analgesics/sedatives. Specific anesthetic choices will also be influenced by an anesthesiologist's individual practice.

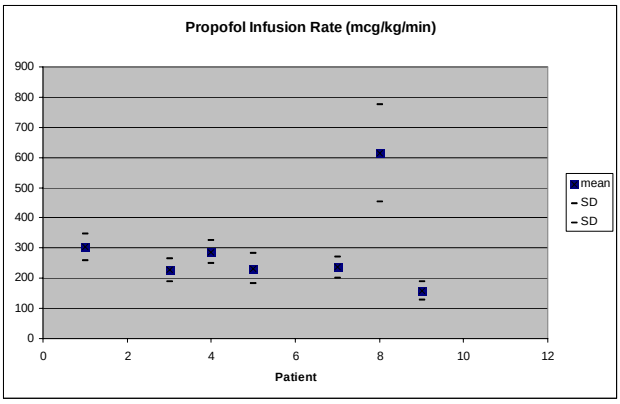
Propofol Infusion Rate (mcg/kg/min)
900
800
700
600
500
400
300
200
100
0
0
2
4
6
8
10
12
Patient
mean
SD
SD