Morphologic changes in the pediatric epiglottis: An Age-based comparison in normal children using video-bronchoscopy

Author(s): PG Dalal[1], A Feng[2], D Molter[3], A Messner[4], J McAllister[5], D Murray[5]

Affiliation(s): 1 Anesthesiology, Penn State Hershey Medical Center, PA, USA; 2 Anesthesiology, Kaiser Foundation Hospital, Oakland, CA; 3 Otolaryngology and 5 Anesthesiology, Washington University School of Medicine, St Louis, MO; 4 Otolaryngology, Lucile Packard Children's Hospital, Stanford University Medical Center, CA

Introduction: Few studies are available that characterize growth and development changes that occur in the upper airway. The changes in relative size of the epiglottis, larynx, cricoid and trachea during growth and development form the basis of a number of important clinical decisions in pediatric practice. While most studies have described the morphologic changes in pediatric larynx during growth and development, few have actually focused on the epiglottis and fewer so on the epiglottic angle in the coronal versus the sagittal plane. The epiglottis is often described as a hard, narrow and omega-shaped structure in infants and young children that becomes a broad, patulous and achieves a crescentic form in adult patients as seen via the superior view (1,2, figures 1,2)). Indeed, it is this omega or inverted U-shape that is considered the cause of airway obstruction as well as creating problems with the glottic view during laryngoscopy (1-3). A method to quantitatively assess the size and shape of the epiglottis that could be used to characterize changes associated with growth and development is not currently available. The aim of this study was to assess the dimensions of the superior aspect of the epiglottis using videobronchoscopy in children with normal upper airway.

Figure 1

Figure 2

Method: Following IRB approval and written informed parental consent, 16 ASAphysical status 1 or 2 patients without known airway anomalies were included in the study. After application of routine monitoring and administration of a standard anesthetic induction technique, neuromuscular paralysis was achieved with rocuronium 0.5mg/kg. Following calibration on a graph paper with a rigid bronchoscope at a fixed distance, videobronchoscopic images of the superior aspect of the epiglottis were obtained from the same distance. The images were analysed off-line using the Image J software (Rasband WS; ImageJ, NIH, Bethesda, USA). The geometric angle of the epiglottis in the coronal plane was measured by obtaining two lines – one on either side formed by joining the point on the epiglottis from where the ary-epiglottic folds commence posterolaterally to the center-point of the superior aspect of the epiglottis anteriorly (figure 3). The transverse diameter of the epiglottis was measured by drawing

a transverse line across the posterior aspect of the epiglottis as shown (figure 3). Statistical analysis was performed using Sigma stat version 3.11 Copyright © 2004 Systat Software,Inc. Pearson product moment correlation and linear regression analysis were used for significance testing. A p-value<0.05 was considered significant.

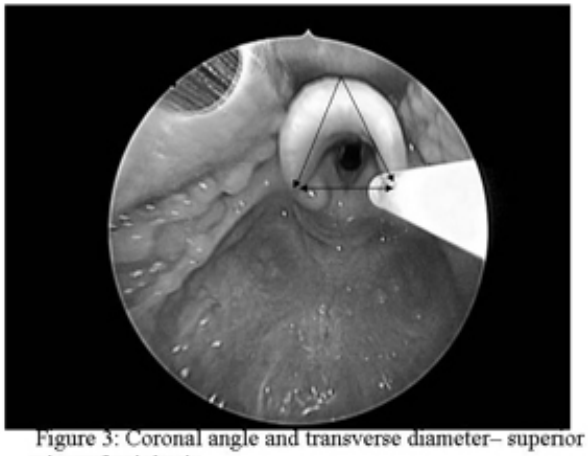

Figure 3: Coronal angle and transverse diameter– superior view of epiglottis

Results: Of the 16 children, mean age was 54.4 months (± 29.4, range 8 – 94months), mean weight 18.2kg (±6, range 6 – 31.3) and the mean height was 105cm (±18.9, range 66 – 134). The mean coronal angle of the superior aspect of the epiglottis as described above was 62.8 degrees (± 13.6, range 45 – 84 degrees). The mean transverse diameter was 3.9mm (± 0.9, range 2.5 – 6.4). There was a positive correlation between the coronal angle epiglottis and age. This was given by the predictive equation: ANGLE = 40.8 + (0.4 x AGE), r=0.86, p<0.001. There was a positive correlation between angle vs weight (r =0.7, p=0.001) and angle vs height (r =0.73, p=0.001). The relation between angle and age is as shown in the graph (figure 4). There was a poor correlation between age, weight or height and the transverse diameter (r=0.1, p=0.6) of the epiglottis.

Figure 4: Coronal angle (degrees) vs Age (months)

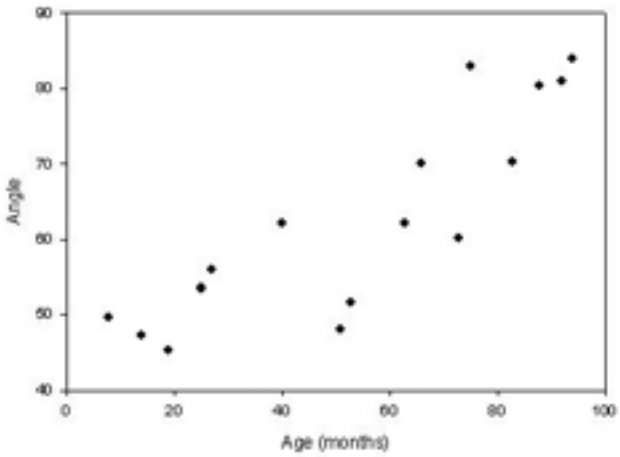

Discussion: The shape and size of the epiglottis alters the approach as well as considerations for airway management in infants and younger children, such as positioning of the patient and choice of a

laryngoscopic blade. In this study, we offer a method to characterize changes in epiglottis size and shape associated with growth and development. Previous studies have described the laryngeal dimensions in children using magnetic resonance imaging or cadaver specimens without reference to the epiglottis. In this study, using rigid video-endoscopy to view the upper airway, we found that the coronal angle of the epiglottis appears to correlate well with age, height and weight of the child. This coronal angle of the epiglottis changes from a more acute to a less acute and nearly approaching a right angle form as seen from the graph at around the age of 6 years of age. However, the transverse diameter or the width of the epiglottis did not correlate with age. Additional investigations would be helpful to characterize the changes in epiglottis dimensions associated with growth and development and application to assessment of airway obstruction in children with upper airway diseases and obstructive sleep apnea.

Reference:

1 Motoyama EK, Davis PJ. Smith's Anesthesia for Infants and Children, 1996 Mosby-year book; 6th edition, chapter 9: 297-9
2 Benumof JL. Airway management – Principles and Practice, 1996 Mosby-year book, Inc, chapter 29: 585-637
3 Walker RW. Management of the difficult airway in children. J R Soc Med;94:341-344
4 Litman RS. Anesthesiology 2003;98:41-45
5 Eckel et al. Ann Otol Rhinol 1999;108(3):232-8