Cervical Myelomeningocele (cMMC) in an 8 month old infant

AUTHORS: RL da Graca, MCJ Tran, ML Davidson

AFFILIATION: University of Medicine and Dentistry School of Medicine, Newark, New Jersey

Introduction: Cervical myelomeningocele (cMMC) is a rare form of spinal dysraphisms comprising less than 5% of all neural tube defects.[1] Few series and case reports have been published describing cMMC outcomes and sequlae. We describe our anesthetic management of an 8 month old infant with cMMC.

Methods: Case report of a baby girl with congenital cMMC who was vaginally delivered at term born to a 39 year old mother with an unremarkable prenatal history. The infant's birthweight was 3400 grams. Physical exam revealed a small mass with full thickness skin and a tuft of hair in the cervical region. The infant did not demonstrate any neurologic deficits, gastrointestinal or urinary problems. At 8 months of age patient presented for repair of the cervical myelomeningocele which remained stable in size since birth (figure 1). Her preoperative urologic workup was normal and a head MRI (fig.2) revealed no hydrocephalus or chiari malformation. A cervical spinal MRI (fig. 3) revealed a myelomeningocele at regions C2-3 without cysts.

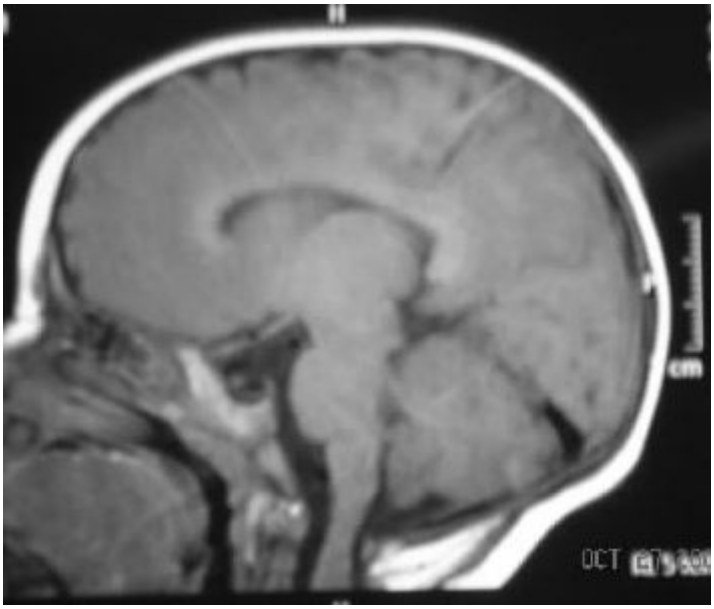

Induction of anesthesia was performed with mask induction using sevoflurane 8%, nitrous oxide 7 lpm, and oxygen 3 lpm. Cervical in-line neck stabilization was performed in order to minimize potential neurologic complications. Vecuronium 0.1 mg/kg was used to facilitate oral intubation with no further muscle relaxant used during the case. She had a Mallampati Class I airway and was intubated with a 4.5 uncuffed endotracheal tube with a leak measured at 25 cmH_20. Infant was placed in the prone postion (figure 4) that demonstrates the relationship of the mass size (1x1x1.5cm). Anesthesia was maintained with 0.5 MAC of sevoflurane, propofol drip at 100 mcg/kg/min, and remifentanyl drip at 0.2 mcg/kg/min in order to facilitate SSEP monitoring throughout the case.

Results: There were no interval events or surgical complications throughout the case and additional long acting opiods were titrated in order to facilitate pain control prior to extubation. Surgical time lasted 3 hours and 44 minutes. Blood loss during the case was minimal and the infant was successfully extubated and transferred to the pediatric intensive care unit for further observation. Surgical pathology was consistent with untethered myelomeningocele. Infant was discharged postoperative day # 2 from the hospital with normal examination and no post-operative neurologic or urinary complications.

Discussion: Neural tube defects (NTD) is the second most common neurologic congenital anomaly leading to disability in childhood following cerebral palsy.[1] Spinal dysraphism occurs in approximately 2/1000 births worldwide with the overall incidence decreasing in the United States. Multiple factors, including environmental and genetic have been associated with the development of NTD formation, with maternal folate deficiency being the key factor.[2] Cervical myelomeningocele occurs in less than 5% of all NTD and it is associated with less motor deficits, urinary voiding difficulties, and urologic deformities than lower neural tube defects.[3] Chiari II malformation which is more commonly associated with open NTD has been reported in 44-62% in patients with cMMC. Hydrocephalus, which is usually present and associated with chiari malformations and lumbar defects, is not associated with cMMC.[4] Two types of cMMC malformations are described; the more common is a fibroneurovascular stalk extending from the cervical cord into the lining of the sac, and the less common one is one that splits into 2 hemicords separated by a midline fibrous septum. Surgical intervention, although cosmetic, is also preventative since patients with cMMC are often asymptomatic early in life but may still develop tethering of the cord as adults with neurologic deterioration.[4,5] Our case demonstrates the importance of how cMMC differs from the usual lower NTD and the anesthetic considerations in this patient population.

1. Meyer-Heim AD, Klein A, Boltshauser E: Cervical myelomeningocele: follow-up of five patients. Eur J Paediatr Neurol 7:407-412

2. Habibi Z, Nejat F et al. Cervical myelomeningocele; Clinical Report. Neurosurgery 58:1168-1175, 2006
3. Perez LM, Wilbanks, JT. Urological outcome of patients with cervical and upper thoracic myelomeningocele. Journal of Urology. 2000:164;962-964
4. Pang D, Dias MS. Cervical myelomeningoceles. Neurosurgery. 1993; 33:363-373
5. Eller TW, Bernstein LP. Tethered cervical spinal cord: case report. J Neurosurg. 1987:76